

Ultrasound Image Guidance for Cardiac Interventions

Terry M. Peters^{a,c}, Danielle F. Pace^{a,d}, Pencilla Lang^a, Gérard M. Guiraudon^{a,c},
Douglas L. Jones^{b,c} and Cristian A. Linte^{a,e}

^aImaging Research Laboratories, Robarts Research Institute - London ON Canada

^bDepartment of Physiology and Pharmacology, Univ. of Western Ontario - London ON Canada

^cCanadian Surgical Technologies and Advanced Robotics - London ON Canada

^dKitware Inc. - Carrboro NC USA

^eBiomedical Imaging Resource, Mayo Clinic - Rochester MN USA

ABSTRACT

Surgical procedures often have the unfortunate side-effect of causing the patient significant trauma while accessing the target site. Indeed, in some cases the trauma inflicted on the patient during access to the target greatly exceeds that caused by performing the therapy. Heart disease has traditionally been treated surgically using open chest techniques with the patient being placed “on pump” — i.e. their circulation being maintained by a cardio-pulmonary bypass or “heart-lung” machine. Recently, techniques have been developed for performing minimally invasive interventions on the heart, obviating the formerly invasive procedures. These new approaches rely on pre-operative images, combined with real-time images acquired during the procedure. Our approach is to register intra-operative images to the patient, and use a navigation system that combines intra-operative ultrasound with virtual models of instrumentation that has been introduced into the chamber through the heart wall. This paper illustrates the problems associated with traditional ultrasound guidance, and reviews the state of the art in real-time 3D cardiac ultrasound technology. In addition, it discusses the implementation of an image-guided intervention platform that integrates real-time ultrasound with a virtual reality environment, bringing together the pre-operative anatomy derived from MRI or CT, representations of tracked instrumentation inside the heart chamber, and the intra-operatively acquired ultrasound images.

1. INTRODUCTION

1.1. Conventional Cardiac Surgery

A large number of conditions require physical therapeutic intervention, which often exposes the patient to additional risks arising from the approach taken to access the target tissue, as opposed to the therapy itself. Cardiac therapy may consist of the replacement or repair of a malfunctioning valve, restoration of myocardial perfusion by inserting a stent or performing a bypass graft, or electrical isolation of tissue regions that cause abnormal heart rhythm by creating scar tissue by heating or freezing. Cardiac interventions are unique in several perspectives, namely, access, restricted visualization and surgical instrument manipulation, as well as the dynamic nature of the heart. Procedure invasiveness extends beyond the typical measurement of the incision size, and in fact, arises from two equally important sources: access to the surgical target via a median sternotomy and rib-spreading, and the use of cardiopulmonary bypass after the heart is stopped. Supplying circulatory support via cardiopulmonary bypass (i.e. heart-lung machine) represents a significant source of invasiveness that may lead to severe inflammatory response and neurological damage.¹ Moreover, despite various approaches employed to stabilize the motion of the heart at the site of interest during surgery,² the delivery of therapy to a soft tissue organ enclosing a blood-filled environment in continuous motion is still a significant challenge. Successful therapy requires versatile instrumentation, robust visualization, and superior surgical skills.

Further author information:

Terry M. Peters (E-mail: tpeters@robarts.ca)

Imaging Research Labs, Robarts Research Institute: 100 Perth Dr., P.O.Box: 5015, London ON N6A 5K8 Canada.

1.2. Minimally Invasive Procedures

Due to the challenges associated with visualization and access, cardiac interventions have been among the last surgical applications to embrace the movement toward minimal invasiveness.³ This movement originated in the mid-1990s following the introduction of laparoscopic techniques and their use in video-assisted thoracic surgery. The adoption of less invasive techniques posed significant problems in terms of their workflow integration and yield of clinically acceptable outcomes. However, the morbidity associated with the *surgery* rather than the *therapy*, together with the successful experience with the less invasive approaches in other surgical specialties, have fueled their emergence into cardiac therapy.

Multiple access routes including partial sternotomies, limited access thoracotomies or catheter-based techniques have been used as an alternative to the traditional full median sternotomy.³ Initial attempts were aimed at performing coronary artery bypass graft (CABG) surgery via minimally invasive access to the arrested heart⁴ without cardiopulmonary bypass.⁵ A number of centres reported their experience with robot-assisted atrial septal defect (ASD) and patent foramen ovale closure,⁶ mitral valve repair and replacement,⁷ transluminal^{8,9} or transapical^{10,11} aortic valve implantation, or percutaneous pulmonary vein isolation for treatment of atrial fibrillation.¹² The increasing use of endovascular techniques constitutes one of the most rapid changes noted in cardiac interventions. As a result, vascular-guided therapy delivery has become the ultimate, least invasive cardiac therapy approach.¹³

1.3. Imaging and Image Guidance

Over the past couple of decades, medical imaging has provided a means for visualization and guidance during interventions where direct visual feedback could not be achieved without significant trauma; such procedures are commonly referred to as image-guided interventions (IGI). Within the IGI community, an image-guided procedure is any minimally invasive intervention that uses imaging for guidance. The typical components/stages of an IGI system/procedure workflow are outlined in¹⁴ and consist of pre-operative imaging, surgical tracking, intra-operative imaging, patient registration, and real-time visualization and surgical guidance. However, two major challenges must be addressed to enable beating heart interventions: special instrumentation that is compatible with the minimally-invasive surgical access and the dynamic cardiac environment must be designed, and appropriate surgical guidance must be provided.

Initial image-guided techniques, including robot-assisted procedures, relied on thoroscopic video or fluoroscopic imaging for surgical guidance.^{15,16} However, the superior image quality and real-time frame rate provided by endoscopic video is only of use during epicardial procedures or intracardiac interventions performed under cardiac arrest, as video cannot “see through” the blood-filled cavities.

The advent of “CT fluoroscopy” has opened the door for promoting CT as a high-quality intra-procedure image-guidance technique. Lauritsch *et al.*¹⁷ have investigated the feasibility of C-arm guidance both *in vitro*, using phantom experiments, as well as in *in vivo* pre-clinical studies. In spite of their excellent capability differentiating bone from soft tissue, neither CT nor X-ray fluoroscopy images possess the necessary contrast to identify various features in the cardiac anatomy without contrast enhancement, and they expose both the patient and clinical staff to harmful ionizing radiation.

McVeigh *et al.*¹⁸ have shown that interventional MRI systems can provide the surgeon with detailed and comprehensive dynamic cardiac images for intra-procedure guidance. However, the use of MRI as an interventional modality has been limited due to the restricted surgical access, incompatibility with most of the standard operating room (OR) equipment, and increased expense and complexity of the procedures.

As an alternative to CT or MRI, ultrasound (US) imaging is an attractive modality for intra-procedure guidance, especially due to its safety, low cost, wide availability, and lack of ionizing radiation. The main drawback of US is that standard 2D images cannot appropriately portray a 3D surgical scene, which often includes delivery instruments and anatomical targets. This visualization impediment can be improved by complementing the 2D images with appropriate anatomical context provided by high-quality pre-operative information. In fact, recently developed image-guided therapy systems for cardiac surgery have fused data from pre- and intra-operative imaging and tracking technologies to form sophisticated visualizations for surgical guidance.¹⁹

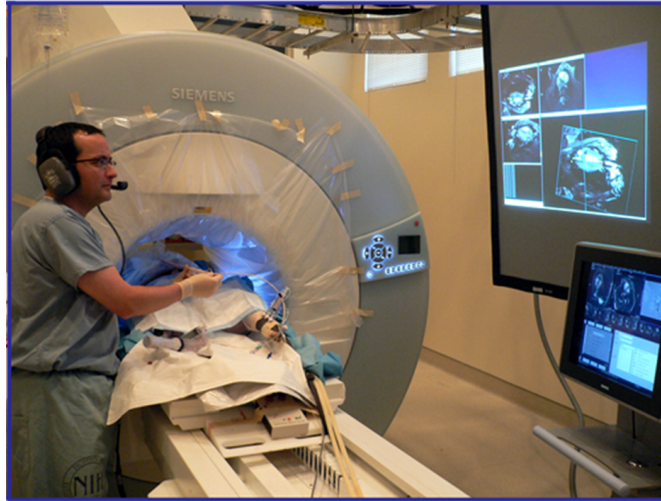

Figure 1. Interventional cardiac MRI suite employing a modified clinical scanner with a shorter bore and a wider opening. Image adapted from McVeigh *et al.* Springer © 2008.

2. INTERVENTIONAL ULTRASOUND IMAGING

Ultrasound has been employed in interventional guidance since the early 1990s,²⁰ initially for neurosurgical procedures. US can acquire real-time images at various user-controlled positions and orientations, with a spatial resolution ranging from 0.2 to 2 mm. Moreover, US systems are inexpensive, mobile, and compatible with the OR equipment. It is generally agreed that the quality of US images is inferior to that of the CT or MR images.²¹ The presence of multiple speckle reflections, shadowing, and variable contrast are some of the disadvantages that have contributed to the slow progress of employing US imaging intra-operatively. Several approaches to enhance anatomical visualization have included the acquisition of 2D US image series to generate volumetric datasets,²² optical or magnetic tracking of the 2D US transducer to reconstruct 3D images,²³ and fusion of US and pre-operative CT or MRI images.^{24,25}

US transducers of varying size and invasiveness, some of which image natively in 3D, have been employed for cardiac interventions. Furthermore, integration of US imaging with surgical tracking technologies has enabled visualization of the acquired images relative to the tracked surgical instruments, as described in the following sections.

2.1. Transthoracic Echocardiography - TTE

These probes are held against the patient's chest and are simple to use and completely non-invasive. However, acoustic windows where the ribs and lungs do not impede imaging are limited, and depth penetration is problematic in obese patients or those with chronic lung disease. Because the probe must remain in contact with the patient's chest, the surgeon needs to manipulate the US transducer at the same time as the instruments, leading to a cumbersome workflow.

2.2. Transesophageal Echocardiography - TEE

TEE transducers are inserted into the patient's esophagus or upper stomach to image from directly behind the heart. Most are multi-planar, meaning that the imaging plane can be electronically rotated through 180°. The viewing direction can also be manipulated by translating, flexing and tilting the probe. The proximity of the probe to the heart allows for higher frequency transducers, which increases spatial resolution and overall image quality compared to TTE. During interventions, the transducer is conveniently out of the way inside the patient, but this necessitates general anesthesia and makes imaging more technically challenging.

2.3. Intracardiac Echocardiography - ICE

Fixed to a steerable catheter, these transducers are navigated directly into the heart via the femoral or jugular vein. In particular, ICE is often used to visualize interventional catheters during percutaneous procedures. A very high imaging frequency provides excellent image quality and general anesthesia is not required. However, the single-use nature of ICE makes it expensive. In addition, ICE probes are difficult for the clinician to manipulate inside the heart, and given the proximity of the transducer to the imaged tissue, ICE images have a limited field of view and are difficult to interpret without additional anatomical context.

2.3.1. Reconstructed 3D Imaging

A single volume, or a time series of 3D ultrasound images can be built from multiple 2D images that cover 3D space, and are acquired by moving the ultrasound probe manually or mechanically.²⁶ Cardiac gating is required when imaging the beating heart with this approach. Each 2D US image must be accurately localized in 3D space by tracking the ultrasound probe, or, for mechanical probe manipulation, using actuator feedback (although sensor-less approaches do exist). Ultrasound reconstruction is flexible and can generate 3D images with good spatial resolution and a large field of view (**Fig. 2**), but it can be a lengthy procedure and is subject to artifacts caused by tracking error, cardiac gating error, or respiratory or patient motion.

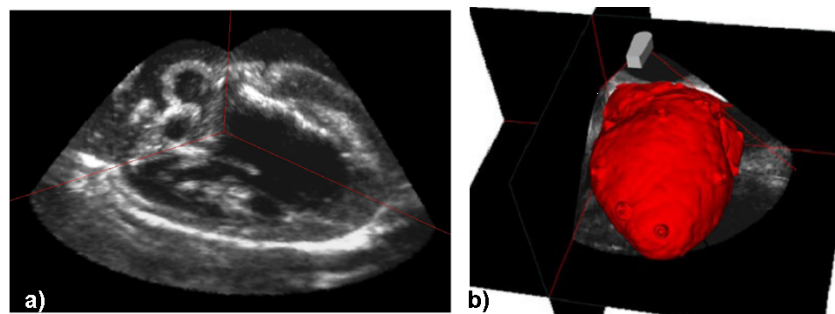


Figure 2. Commonly employed optical a) Example 3D ultrasound reconstruction of an excised porcine heart in a water bath, acquired using the TEE probe with a rotational acquisition; b) Example visualization of a reconstructed 4D ultrasound dataset registered to a dynamic cardiac surface model (single frame showed here) using a beating heart phantom (The Chamberlain Group, Great Barrington, MA, USA).

2.3.2. Real-time 3D Imaging

A 2D matrix array transducer with electronic beam steering natively acquires pyramidal 3D images at 20-30 frames per second with real-time volume rendering.²⁷ Both TTE and TEE transducers are currently available and real-time 3D ICE is on the horizon. Trade-offs between spatial resolution, frame rate and field of view are caused by the finite speed of sound in tissue, so only a small section of the heart can be imaged at any point in time. It is therefore common to stitch together several ECG-gated images acquired over multiple cardiac cycles from different viewing directions with electronic beam steering. Such “wide-angle” scans are generated without probe tracking while assuming a stationary transducer and patient. The resulting composite scans are subject to stitch artifacts at the interfaces between the original real-time 3D images.

3. ULTRASOUND DATA MANIPULATION AND IMAGE FUSION

Image processing and analysis algorithms designed specifically for ultrasound images are required when integrating echocardiography within image-guided therapy systems. Strategies for fusing ultrasound imagery with other datasets are particularly important. Intra-operative ultrasound images are often used to bring preoperative images into the coordinate system of the intra-operative patient (patient-to-image registration). Tracking technologies used to align data spatially must be integrated into the operating room while not impeding ultrasound imaging or standard workflows. Finally, ultrasound imagery must be integrated within three-dimensional scenes alongside additional image, geometric and/or functional data.

3.1. Image registration

Image registration is critical for image-guided therapy and multimodal data fusion. Monomodal and multimodal registration of cardiac ultrasound images remains challenging because they show few distinctive features and because of ultrasound's relatively poor image quality. Approaches for image-to-patient registration via intra-operative ultrasound have been based on matching anatomical landmarks such as the valve annuli,²⁸ aortic centerline²⁹ and endocardial surface coordinates.³⁰

Intensity-based image registration is often ideal for intra-operative use since it does not rely on potentially inaccurate feature localization, potentially requires no user interaction, and in some cases can be implemented in real-time. Example algorithms registering intra-operative ultrasound to high-quality CT or MRI cardiac images include those of Sun *et al.*,²⁴ who maximized the normalized cross-correlation between 2D ICE images and the gradient magnitude of intra-operative CT images, Huang *et al.*,²⁵ who enabled fast intra-operative registration between tracked 2D ultrasound and preoperative CT images by computing a very close registration initialization, and King *et al.*,³¹ who optimized the statistical likelihood that 3D ultrasound images arose from a preoperative surface model using a simple model of US physics.

3.2. Tracking

Real-time tracking of moving surgical tools and imaging devices is required for data to be properly displayed relative to each other. Although optical tracking systems can be used to track intraoperative transthoracic probes, their line-of-sight constraints make electromagnetic tracking more suitable when using transesophageal or intracardiac echocardiography (**Fig. 3**). Image-based tracking of surgical tools within ultrasound images using physical markers³² and voxel classification³³ has also been investigated, but is not in widespread use at present.




Figure 3. Commonly employed optical a) Polaris SpectraTM from NDI and b) Micron TrackerTM from Claron Technologies and magnetic tracking systems: c) AuroraTM from NDI and d) 3D GuidanceTM from Ascension.

Relatively simple surgical guidance systems visualizing tracked real-time 2D US alongside virtual representations of tracked surgical tools, such as needles or anastomosis (fastening) devices, have been proposed for beating-heart intracardiac interventions and even for prenatal cardiac interventions to guide needles through the maternal abdomen and into the fetal heart.

3.3. Volume Rendering Image Fusion

Although overlaying virtual representations of tracked surgical tools onto echocardiography should enhance image interpretability during surgical tasks, greater improvements can be provided by fusing echocardiography with information from other imaging modalities.

Volume rendering is the most common technique for visualizing real-time 3D ultrasound within image guidance systems designed for cardiac therapy, as it utilizes all the original 3D imaging data, rather than discarding most of it when surfaces are extracted using segmentation. “Viewing rays” are cast through the intact volumes and individual voxels in the dataset are mapped onto the viewing plane, maintaining their 3D relationship while making the display appearance meaningful to the observer.

The interventional system described by Wein *et al.*,³⁴ which registers real-time 3D ICE images with intra-operative C-arm CT imagery, uses volume rendering to visualize the ultrasound data within its augmented reality display. Ma *et al.*²⁹ have developed a guidance system fusing complementary X-ray and transthoracic 3D echocardiography data, using a master-slave robotic system to manipulate the ultrasound probe in the presence of X-ray radiation and overlaying volume rendered 3D ultrasound onto the the 2D X-ray images.

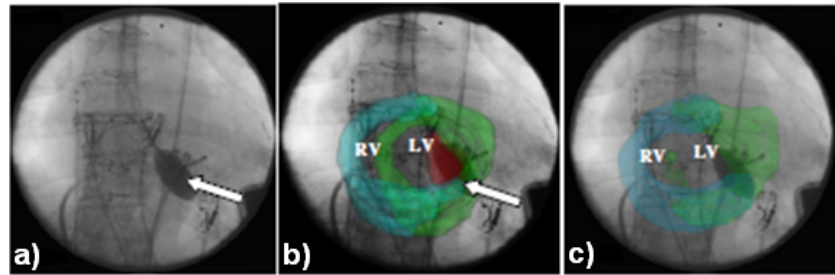


Figure 4. a) Traditional 2D X-ray image used for catheter navigation; b) Manual segmentations of the left (green) and right ventricle (blue) and electrical measurement catheter (red) overlaid onto 2D x-ray image; c) Volume rendering of the masked 3D echo image was also used and overlaid onto the 2D x-ray images. Image adapted from Ma *et al.* IOP[©] 2009.

Recently, using GPUs, artifact-free interactive volume rendering of medical datasets was achieved³⁵ without compromising image fidelity, as also demonstrated by Zhang *et al.* (**Fig. 5**).³⁶

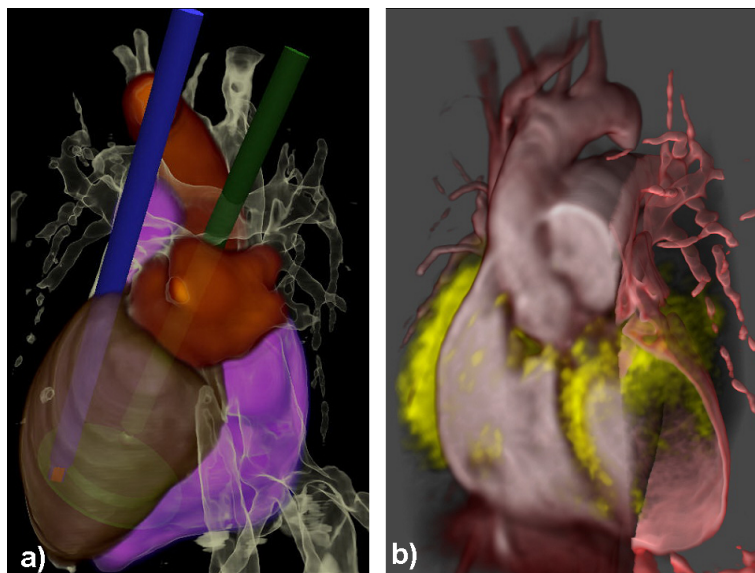


Figure 5. a) Procedure simulation showing volume rendered cardiac MR dataset augmented with surgical instruments, displayed using different translucency levels for feature enhancement; b) Fused cardiac MR and 3D US datasets, showing enhancement of the pre-operative MR data. Images courtesy of Qi Zhang, PhD, Robarts Research Institute.

4. PRE-CLINICAL AND CLINICAL APPLICATIONS

Although US imaging technology has been around for quite some time, it was mainly employed as a diagnostic imaging tool. Recently, however, the use of US has expanded toward interventional imaging, leading to several pre-clinical and clinical successes in surgical guidance, while others are still under development.

4.1. Fluoroscopy & TEE-guided Aortic Valve Implantation

Transapical aortic valve implantations have received significant attention over the past few years. Such procedures have been successful under real-time MR imaging, as well as real-time cone-beam CT and US imaging. Walther *et al.*¹¹ have reported the use of real-time fluoroscopy guidance combined with echocardiography to guide the implantation of aortic valves via the left ventricular apex during rapid ventricular pacing. The guidance environment integrates both a planning and a guidance module. The pre-operative planning is conducted based on DynaCTTM Axiom Artis images (Siemens Inc., Erlangen, Germany) and interactive anatomical landmark selection to determine the size and optimal position of the prosthesis. The intra-operative fluoroscopy guidance allows tracking of the prosthesis and coronary ostia, while TEE enables real-time assessment of valve positioning.³⁷ The main benefit of these contemporary CBCT imaging systems is their ability to provide 3D organ reconstructions during the procedure. Because the fluoroscopy and CT images are intrinsically registered, no further registration is required to overlay the model of the aortic root reconstructed intra-operatively with the real-time fluoroscopy images.³⁸ Moreover, since this therapy approach makes use of imaging modalities already employed in the OR, it has the potential to be adopted as a clinical standard of care for such interventions.

4.2. US-guided Robot-Assisted Mitral Valve Repair

Real-time 3D (4D) US imaging has been employed extensively in clinical practice, enabling the performance of new surgical procedures,^{39,40} and making possible real-time therapy evaluation on the beating heart. However, the rapid cardiac motion introduces serious challenges to the surgeons, especially for procedures which require the manipulation of moving intracardiac structures. Howe *et al.*⁴¹ have proposed the use of a 3D US-based robotic motion compensation system to synchronize instruments with the motion of the heart. The system consists of a real-time 3D US tissue tracker that is integrated with a 1 degree-of-freedom actuated surgical instrument and a real-time 3D US instrument tracker. The device first identifies the position of the instrument and target tissue, then drives the robot such that the instrument matches the target motion.

For mitral valve repair procedures, the motion compensation system was simplified according to the clinical observation that the mitral annulus follows mainly a one-dimensional translation along the left atrium - left ventricle axis. Two instruments were introduced through the wall of the left atrium: the first instrument deployed an annuloplasty ring with a shape-memory-alloy frame, while the second instrument applied anchors to attach the ring to the valve annulus. This approach allows the surgeon to operate on a “virtually motionless” heart when placing the annuloplasty ring and anchors. Initial studies have demonstrated the potential of such motion-compensation techniques to increase the success rate of surgical anchor implantation. Moreover, in a recent study,⁴² this group also reported sub-millimeter accuracy in tracking the mitral valve using a similar motion-compensation approach for catheter servoing.

4.3. Model-enhanced US-guided Intracardiac Interventions

The development of model-enhanced US assisted guidance draws its origins from the principle that therapeutic interventions consist of two processes: navigation, during which the surgical instrument is brought close to the target, and positioning, when the actual therapy is delivered by accurately placing the tool on target. The integration of pre- and intra-operative imaging and surgical tracking enables the implementation of the navigation-positioning paradigm formulated in this work. The pre-operative anatomical models act as guides to facilitate tool-to-target navigation, while the US images provide real-time guidance for on-target tool positioning.

This platform has been employed pre-clinically to guide several *in vivo* intracardiac beating heart interventions in swine models, including mitral valve implantation and septal defect repair.²⁸ In our work, access to the chambers of the beating heart was achieved using the Universal Cardiac Introducer (UCI)[®]⁴³ attached to the left atrial appendage of the swine heart exposed via a left minithoracotomy. The guidance environment employed magnetically tracked real-time 2D TEE augmented with pre-operative models of the porcine heart and virtual

representations of the valve-guiding tool and valve-fastening tool. The procedure involved the navigation of the tools to the target under guidance provided by the virtual models, followed by the positioning of the valve and application of the surgical clips under real-time US imaging (**Fig. 6**).

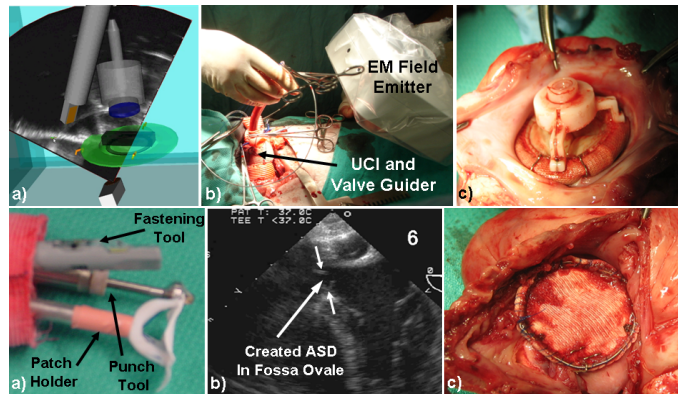


Figure 6. Mitral valve implantation - upper panel: a) Guidance environment showing virtual models of the US probe and surgical tools; b) OR setup during model-enhanced US guided interventions; c) Post-procedure assessment image. Septal defect repair - lower panel: a) Tools employed during the ASD creation and repair; b) 2D US image showing the septal defect; c) Post-operative image showing successful ASD repair. Image adapted from Linte *et al.* Springer[©] 2009.

The ASD repair procedure was similar to the mitral valve implantation, however the surgical target was not readily defined. The septal defect was created in the swine models by removing a circular disc of tissue from the fossa ovale under US guidance, using a custom-made hole-punch tool (15 mm diameter) introduced via the UCI[®]. The created septal defect was confirmed using colour Doppler US for blood flow imaging. The repair patch was guided to the target under virtual model guidance. Once on target, the surgeon correctly positioned the patch on the created ASD and anchored it to the underlying tissue under real-time US image guidance (**Fig. 6**).

4.4. ICE-guided Ablation Therapy

Recently, intra-operative 2D ICE has been proposed as an alternative to pre-operative MR/CT for the generation of endocardial surface models. ICE-derived surface models have been used within surgical guidance systems used in patients to perform pulmonary vein and linear ablations⁴⁴ and left ventricular tachycardia ablations.⁴⁵ A set of spatially-localized 2D ICE images can be acquired by sweeping a magnetically-tracked 2D ICE probe to view the left atrium, left ventricle, pulmonary veins or any other structures of interest, typically under ECG and respiratory gating. Although ICE-derived surface models have a lower spatial resolution than those segmented from preoperative MR or CT, they can be generated in the operating room and may be argued to provide the intra-operative heart with higher fidelity.

Moreover, intra-operative endocardial surface data derived from 2D ICE have been used to integrate preoperative MR/CT surface models with the intraoperative patient. This approach takes advantage of ICE's ability to collect endocardial surface points without deforming the cardiac wall, which leads to improved registration accuracy while still integrating a high-quality surface model, as demonstrated by Zhong *et al.*³⁰ Real-time 2D ICE imaging can also be integrated into the surgical guidance system along with a cardiac model and representation of the ablation catheter, as demonstrated by den Uijl *et al.*⁴⁶

4.5. Cardiac Revascularization and Resynchronization Therapy

Coronary artery revascularization (CAR) and cardiac resynchronization therapy (CRT) may improve systolic performance, survival, and quality of life in patients with left ventricular dysfunction. 3D vascular imaging techniques, such as coronary CT or MR angiography, have been used to characterize vascular targets⁴⁷ and to plan both CAR and CRT interventions.⁴⁸ More recently, these vascular images have been fused with spatially

matched 3D myocardial scar imaging to provide 3D maps of both relevant vascular structures and related myocardial scar.⁴⁹ While visual registration of these structures appears to influence therapeutic decisions, the role of these hybrid images for intra-procedural guidance of CAR or CRT needs further investigation.

Revascularization procedures are performed using either percutaneous, fluoroscopically-guided delivery of coronary stents, or surgically, through CABG. The pre-procedural vascular-scar models have the potential to guide the selection of vascular targets based on the viability of the tissue in the respective territories.⁵⁰ Therefore, a simultaneous, synchronized display showing segmental activity obtained from US data, and the extent of viability for specific sites provided via MRI scar imaging, may be clinically valuable.

This information is also relevant to the delivery of the coronary sinus pacemaker leads for resynchronization therapy. These leads are fluoroscopically guided into branches of the coronary venous system to advance the mechanical activation of delayed myocardial segments. Ideally, the coronary sinus lead is delivered to the most mechanically delayed myocardial segment that demonstrates an absence of scar. The accomplishment of this goal can be facilitated by the co-registration of US data measuring segmental activity with multi-component cardiac models to intra-operative fluoroscopy. However, future efforts in the development of lead guidance approaches that integrate vascular models, scar distribution, and activation maps must be invested.

5. SUMMARY, CHALLENGES AND FUTURE DIRECTIONS

Many advances have recently been made in US imaging, including miniaturization in the development of ICE, IVUS and RT3D TEE transducers, and in image quality improvement including the development of coded pulses, tissue harmonic imaging, and adaptive image enhancement techniques.⁵¹ Any future improvements in ultrasonic imaging that increase SNR, remove speckle, reduce artifacts, increase spatial resolution or facilitate image display via post-processing will benefit image-guided therapy, as higher image quality greatly facilitates rapid image interpretation during surgical guidance and also makes processing tasks such as image registration and segmentation easier. Of particular interest for intracardiac interventions is the advent of novel RT3D ICE transducers and the continuing development of RT3D TEE.

Many image processing algorithms still require significant user input, and further minimization of manual interaction within the operating room is desired. Furthermore, continued development in real-time image-to-patient registration, real-time ultrasound segmentation and feature tracking, and image-based cardiac gating and tracking approaches would increase clinical penetration of IGT strategies techniques.

Cardiac image guidance already imposes stringent constraints on the design and manufacture of intracardiac instruments, and magnetically tracked US transducers add another level of complexity. Traditional metallic tools cause strong reflections and shadow artifacts under US imaging, becoming less clearly visible when angled parallel to the ultrasound beam, and also reduce the accuracy with which their position and orientation can be determined by the magnetic tracking system. In addition, ultrasound probes themselves may require modifications to facilitate image-guided intracardiac therapy. ICE transducers may be integrated with ablative devices within the same catheter,⁵² or magnetic tracking sensors may need to be integrated within the probe housing of transesophageal transducers.⁵³

Standardization of validation methodologies are also required to ensure proper comparison of different assessments conducted by different groups.⁵⁴ While a wide variety of techniques have been validated in the laboratory or in animal models, as their development continues, more systems will reach the stage where human testing and clinical trials will become necessary.

The most appropriate means to present such surgical navigation data to the clinical staff is another key research objective. The use of real-time ultrasound imaging also presents challenges because it often requires more mental effort to interpret than other modalities. 3D ultrasound in particular is difficult to display, and the most common visualization technique used, namely volume rendering, often does not display internal structures well without extensive operator interaction. Future work should focus on developing specialized display strategies for use with ultrasound data and on examining the human factors associated with image-guided therapy systems used during cardiac interventions.

ACKNOWLEDGMENTS

The authors thank Dr. Daniel Bainbridge, Dr. Micheal Chu, and Dr. Bob Kiaii for sharing their clinical expertise and Dr. Usaf Aladl, Dr. Elvis Chen, Dr. David Gobbi, Dr. Edward Huang, John Moore, Chris Wedlake, Dr. Marcin Wierzbicki, Dr. Andrew Wiles, and Dr. Qi Zhang for their valuable input. In addition, we acknowledge funding for this work that has been provided by the Natural Sciences and Engineering Research Council, Canadian Institutes of Health Research (MOP-179298), Heart & Stroke Foundation of Canada, Ontario Research Fund, and Canadian Foundation for Innovation.

REFERENCES

1. L. H. Edmunds, "Why cardiopulmonary bypass makes patients sick: strategies to control the blood-synthetic surface interface," *Adv Card Surg.* **6**, pp. 131–67, 1995.
2. V. A. Subramanian, J. C. McCabe, and C. M. Geller, "Minimally invasive direct coronary artery bypass grafting: Two-year clinical experience," *Ann Thorac Surg.* **64**, pp. 1648–53, 1997.
3. M. J. Mack, "Minimally invasive cardiac surgery," *Surg Endosc.* **20**, pp. S488–92, 2006.
4. K. E. Matschke, J. F. Gummert, S. Demertzis, U. Kappert, M. B. Anssar, F. Siclari, V. Falk, E. L. Alderman, C. Detter, H. Reichenspurner, and W. Harringer, "The Cardica C-Port system: Clinical and angiographic evaluation of a new device for automated, compliant distal anastomoses in coronary artery bypass grafting surgery - a multicenter prospective clinical trial," *J Thorac Cardiovasc Surg.* **130**, pp. 1645–52, 2005.
5. K. D. Stahl, W. D. Boyd, T. A. Vassiliades, and H. L. Karamanoukian, "Hybrid robotic coronary artery surgery and angioplasty in multivessel coronary artery disease," *Ann Thorac Surg.* **74**, pp. S1358–62, 2002.
6. J. A. Morgan, J. C. Peacock, T. Kohmoto, M. J. Garrido, B. M. Schanzer, A. R. Kherani, D. W. Vigilance, F. H. Cheema, S. Kaplan, C. R. Smith, M. C. Oz, and M. Argenziano, "Robotic techniques improve quality of life in patients undergoing atrial septal defect repair," *Ann Thorac Surg.* **77**, pp. 1328–33, 2004.
7. L. W. Nifong, W. R. Chitwood, P. S. Pappas, C. R. Smith, M. Argenziano, V. A. Starnes, and P. M. Shah, "Robotic mitral valve surgery: A United States multicenter trial," *J Thorac Cardiovasc Surg.* **129**, pp. 1395–404, 2005.
8. D. Dvir, A. Assali, K. Spargias, and R. Kornowski, "Percutaneous aortic valve implantation in patients with coronary artery disease: Review of therapeutic strategies," *J Invasive Cardiol.* **21**, pp. E237–41, 2009.
9. H. R. Andersen, "History of percutaneous aortic valve prosthesis," *Herz* **34**, pp. 343–6, 2009.
10. M. Bollati, E. Tizzani, C. Moretti, F. Sciuto, P. Omede, G. B. Zoccai, G. P. Trevi, A. Abbate, and I. Sheiban, "The future of new aortic valve replacement approaches," *Future Cardiol.* **6**, pp. 351–6, 2010.
11. T. Walther, G. Schuler, M. A. Borger, J. Kempfert, V. Falk, F. W. Mohr, J. Seeburger, Y. Ruckert, J. Ender, A. Linke, and M. Sholz, "Transapical aortic valve implantation in 100 consecutive patients: Comparison to propensity-matched conventional aortic valve replacement," *Eur Heart J.* **31**, pp. 1398–403, 2010.
12. S. Janin, M. Wojcik, M. Kuniss, A. Berkowitsch, D. Erkapic, S. Zaltsberg, F. Ecarnot, C. W. Hamm, H. F. Pitschner, and T. Neumann, "Pulmonary vein antrum isolation and terminal part of the P-wave," *Pacing Clin Electrophysiol. In Press*, 2010.
13. C. S. Joels, E. M. Langan III, D. L. Cull, C. A. Kalbaugh, and S. M. Taylor, "Effects of increased vascular surgical specialization on general surgery trainees, practicing surgeons, and the provision of vascular surgical care," *J Am Coll Surg.* **208**, 2009.
14. R. Galloway and T. M. Peters, "Overview and history of image-guided interventions," in *Image-guided Interventions: Technology and Applications*, T. M. Peters and K. Cleary, eds., pp. 1–21, Springer, Heidelberg, Germany, 2008.
15. A. Cribier, H. Eltchaninoff, A. Bash, N. Borenstein, C. Tron, F. Bauer, G. Derumeaux, F. Anselme, F. Laborde, and M. B. Leon, "Percutaneous transcatheter implantation of an aortic valve prosthesis for calcific aortic stenosis," *Circulation* **106**, pp. 3006–8, 2002.
16. A. Carpentier, D. Loulmet, B. Aupeple, J. P. Kieffer, D. Tournay, P. Guibourt, A. Fiemeyer, D. Meleard, P. Richomme, and C. Cardon, "First computer assisted open heart surgery: First case operated on with success," *Comptes Rendus de l'Academie des Sciences - Series III* **321**, pp. 437–42, 1998.

17. G. Lauritsch, J. Boese, L. Wigström, H. Kemeth, and R. Fahrig, "Towards cardiac C-arm computed tomography," *IEEE Trans Med Imaging* **25**, pp. 922–34, 2006.
18. E. R. McVeigh, M. A. Guttman, P. Kellman, A. A. Raval, and R. J. Lederman, "Real-time, interactive MRI for cardiovascular interventions," *Acad Radiol.* **12**, pp. 1221–27, 2005.
19. T. M. Peters, "Image-guidance for surgical procedures," *Phys Med Biol.* **51**, pp. R505–40, 2006.
20. V. van Velthoven and L. M. Auer, "Practical application of intraoperative ultrasound imaging," *Acta Neurochir. (Wien)* **105**, pp. 5–13, 1990.
21. R. Steinmeier, R. Fahlbusch, O. Ganslandt, C. Nimsky, W. Huk, M. Buchfelder, M. Kaus, T. Heigl, G. Lens, and R. Kuth, "Intraoperative magnetic resonance imaging with the Magnetom Open scanner: Concepts, neurosurgical indications, and procedures: a preliminary report," *Neurosurgery* **43**, pp. 739–47, 1998.
22. R. N. Rohling, A. H. Gee, and L. Berman, "Automatic registration of 3-D ultrasound images," *Ultrasound Med Biol.* **24**, pp. 841–54, 1998.
23. D. F. Pace, A. D. Wiles, J. Moore, C. Wedlake, D. G. Gobbi, and T. M. Peters, "Validation of four-dimensional ultrasound for targeting in minimally-invasive beating-heart surgery," in *Proc. SPIE Medical Imaging 2009: Visualization, Image-Guided Procedures and Modeling*, **7261**, pp. 726115–1–12, 2009.
24. Y. Sun, S. Kadoury, Y. Li, M. John, F. Sauer, J. Resnick, G. Plambeck, R. Liao, and C. Xu, "Image guidance of intracardiac ultrasound with fusion of pre-operative images," in *Proc. Med Image Comput Comput Assist Interv., Lect Notes Comput Sci.* **10**, pp. 60–7, 2007.
25. X. Huang, J. Moore, G. M. Guiraudon, D. L. Jones, D. Bainbridge, J. Ren, and T. M. Peters, "Dynamic 2D ultrasound and 3D CT image registration of the beating heart," *IEEE Trans Med Imaging* **28**, pp. 1179–89, 2009.
26. A. Fenster and D. B. Downey, "Three dimensional ultrasound imaging," *Ann Rev Biomed Engin.* **2**, pp. 457–75, 2000.
27. I. S. Salgo, "3D echocardiographic visualization for intracardiac beating heart surgery and intervention," *J Thorac Cardiovas Surg.* **19**, pp. 325–9, 2007.
28. C. A. Linte, J. Moore, C. Wedlake, D. Bainbridge, G. M. Guitaudon, D. L. Jones, and T. M. Peters, "Inside the beating heart: An *in vivo* feasibility study on fusing pre- and intra-operative imaging for minimally invasive therapy," *Int J CARS* **4**, pp. 113–122, 2009.
29. Y. L. Ma, G. P. Penney, C. A. Rinaldi, M. Cooklin, R. Razavi, and K. S. Rhode, "Echocardiography to magnetic resonance image registration for use in image-guided cardiac catheterization procedures," *Phys Med Biol.* **54**, pp. 5039–55, 2009.
30. H. Zhong, T. Kanade, and D. Schwartzman, "'virtual touch': An efficient registration method for catheter navigation in left atrium," in *Proc. Med Image Comput Comput Assist Interv., Lect Notes Comput Sci.* **4190**, pp. 437–44, 2006.
31. A. King, Y. Ma, C. Yao, C. Jansen, R. Razavi, K. Rhode, and C. Penney, "Image-to-physical registration for image-guided interventions using 3-D ultrasound and an ultrasound imaging model," in *Information Processing in Medical Imaging*, **5636**, pp. 188–201, Lect Notes Comput Sci., 2009.
32. J. Stoll and P. Dupont, "Passive markers for ultrasound tracking of surgical instruments," in *Proc Med Image Comput Comput Assist Interv.*, **3750**, pp. 41–48, Lect Notes Comput Sci., 2005.
33. M. Linguraru, N. Vasilyev, P. del Nido, and R. Howe, "Statistical segmentation of surgical instruments in 3-D ultrasound images," *Ultrasound med Biol* **33**, pp. 1428–1437, 2007.
34. W. Wein, E. Camus, M. John, M. Diallo, C. Duong, A. Al-Ahmad, R. Fahrig, A. Khamene, and C. Xu, "Towards guidance of electrophysiological procedures with real-time 3D intracardiac echocardiography fusion to C-arm CT," in *Proc. Med Image Comput Comput Assist Interv., Lect Notes Comput Sci.* **5761**, pp. 9–16, 2000.
35. O. Kutter, R. Shams, and N. Navab, "Visualization and GPU-accelerated simulation of medical ultrasound from CT images," *Comput Methods Programs Biomed.* **94**, pp. 250–66, 2009.
36. Q. Zhang, R. Eagleson, and T. M. Peters, "Dynamic real-time 4D cardiac MDCT image display using GPU-accelerated volume rendering," *Comput Med Imaging Graph.* **33**, pp. 461–76, 2009.

37. M. E. Karar, M. Gessat, T. Walther, V. Falk, and O. Burgert, "Towards a new image guidance system for assisting transapical minimally invasive aortic valve implantation," in *Proc. IEEE Eng Med Biol.*, pp. 3645–8, 2009.
38. J. Kempfert, V. Falk, G. Schuler, A. Linke, D. Merk, F. W. Mohr, and T. Walther, "Dyna-CT during minimally invasive off-pump transapical aortic valve implantation," *Ann Thorac Surg.* **88**, pp. 2041–2, 2009.
39. Y. Suematsu, G. R. Marx, J. A. Stoll, P. E. DuPont, R. D. Howe, R. O. Cleveland, J. K. Triedman, T. Migaljevic, B. N. Mora, B. J. Savord, I. S. Salgo, and P. J. del Nido, "Three-dimensional echocardiography-guided beating-heart surgery without cardiopulmonary bypass: A feasibility study," *J Thorac Cardiovasc Surg.* **128**, pp. 579–87, 2004.
40. K. Liang, A. J. Rogers, E. D. Light, D. von Allmen, and S. W. Smith, "Three-dimensional ultrasound guidance of autonomous robotic breast biopsy: feasibility study," *Ultrasound Med Biol.* **36**, pp. 173–7, 2010.
41. R. D. Howe, "Fixing the beating heart: Ultrasound guidance for robotic intracardiac surgery," in *Proc. FIMH, Lect Notes Comput Sci.* **5528**, pp. 97–103, 2009.
42. S. B. Kesner, S. G. Yuen, and R. D. Howe, "Ultrasound servoing of catheters for beating heart valve repair," in *Proc. IPCAI, Lect Notes Comput Sci.* **6135**, pp. 168–78, 2010.
43. G. Guiraudon, D. Jones, D. Bainbridge, and T. Peters, "Mitral valve implantation using off-pump closed beating intracardiac surgery: A feasibility study," *Interact Cardiovasc Thorac Surg.* **6**, pp. 603–607, 2007.
44. Y. Okumura, B. D. Henz, S. B. Johnson, C. J. O'Brien, A. Altman, A. Govari, and D. L. Packer, "Three-dimensional ultrasound for image-guided mapping and intervention: methods, quantitative validation, and clinical feasibility of a novel multimodality image mapping system," *Circ Arrhythm Electrophysiol.* **1**, pp. 110–9, 2008.
45. Y. Khaykin, , A. Skanes, B. Whaley, C. Hill, L. Gula, and A. Verma, "Real-time integration of 2D intracardiac echocardiography and 3d electroanatomical mapping to guide ventricular tachycardia ablation," *Heart Rhythm* **5**, pp. 1396–402, 2008.
46. D. W. den Uijl, L. F. Tops, J. L. Tolosana, J. D. Schuijf, S. A. I. P. Trines, K. Zeppenfeld, J. J. Bax, and M. J. Schalij, "Real-time integration of intracardiac echocardiography and multislice computed tomography to guide radiofrequency catheter ablation for atrial fibrillation," *Heart Rhythm* **5**, pp. 1403–10, 2008.
47. H. Gasparovic, F. J. Rybicki, J. Millstine, D. Unic, J. G. Byrne, K. Yucel, and T. Mihaljevic, "Three dimensional computed tomographic imaging in planning the surgical approach for redo cardiac surgery after coronary revascularization," *Eur J Cardiothorac Surg.* **28**, pp. 244–9, 2005.
48. N. R. Van de Veire, J. D. Schuijf, J. De Sutter, D. Devos, G. B. Bleeker, A. de Roos, E. E. van der Wall, M. J. Schalij, and J. J. Bax, "Non-invasive visualization of the cardiac venous system in coronary artery disease patients using 64-slice computed tomography," *J Am Coll Cardiol.* **48**, pp. 1832–8, 2006.
49. Q. Zhang, R. Eagleson, T. M. Peters, and J. White, "A two-level transfer function based method for heart display with vascular tissue and scar enhancement," in *Proc. IEEE International Symposium Biomedical Imaging*, pp. 903–6, 2009.
50. J. A. White, R. Yee, X. Yuan, A. Krahn, A. Skanes, M. Parker, G. Klein, and M. Drangova, "Delayed enhancement magnetic resonance imaging predicts response to cardiac resynchronization therapy in patients with intraventricular dyssynchrony," *J Am Coll Cardiol.* **48**, pp. 1953–60, 2006.
51. R. T. O'Brien and S. P. Holmes, "Recent advances in ultrasound technology," *Clin Tech Small Anim Pract.* **22**, pp. 93–103, 2007.
52. K. L. Gentry and S. W. Smith, "Integrated catheter for 3-D intracardiac echocardiography and ultrasound ablation," *IEEE Trans Ultrason Ferroelectr Freq Control.* **51**, pp. 799–807, 2004.
53. J. Moore, A. Wiles, C. Wedlake, B. Kiaii, and T. M. Peters, "Integration of trans-esophageal echocardiography with magnetic tracking technology for cardiac interventions," in *Proc. SPIE Medical Imaging 2010: Visualization, Image-guided Procedures and Modeling*, **7625**, pp. 76252Y–1–10, 2010.
54. S. DiMaio, T. Kapur, K. Cleary, S. Aylward, P. Kazanzides, K. Vosburgh, R. Ellis, J. Duncan, H. Lemke, N. Hata, R. Kikinis, G. Fichtinger, and F. Jolesz, "Challenges in image-guided therapy system design," *NeuroImage* **37**, pp. S144–51, 2007.